



Microsurgical Resection of a Thoracolumbar Dumbbell-Type Schwannoma With Preservation of the Functional Nerve Root

[Microsurgical Resection of a Lumbar (L1–2) Dumbbell-Shaped Schwannoma With Preservation of the Nerve Root Function]

Jae – Hyuk Shin, MD, PhD

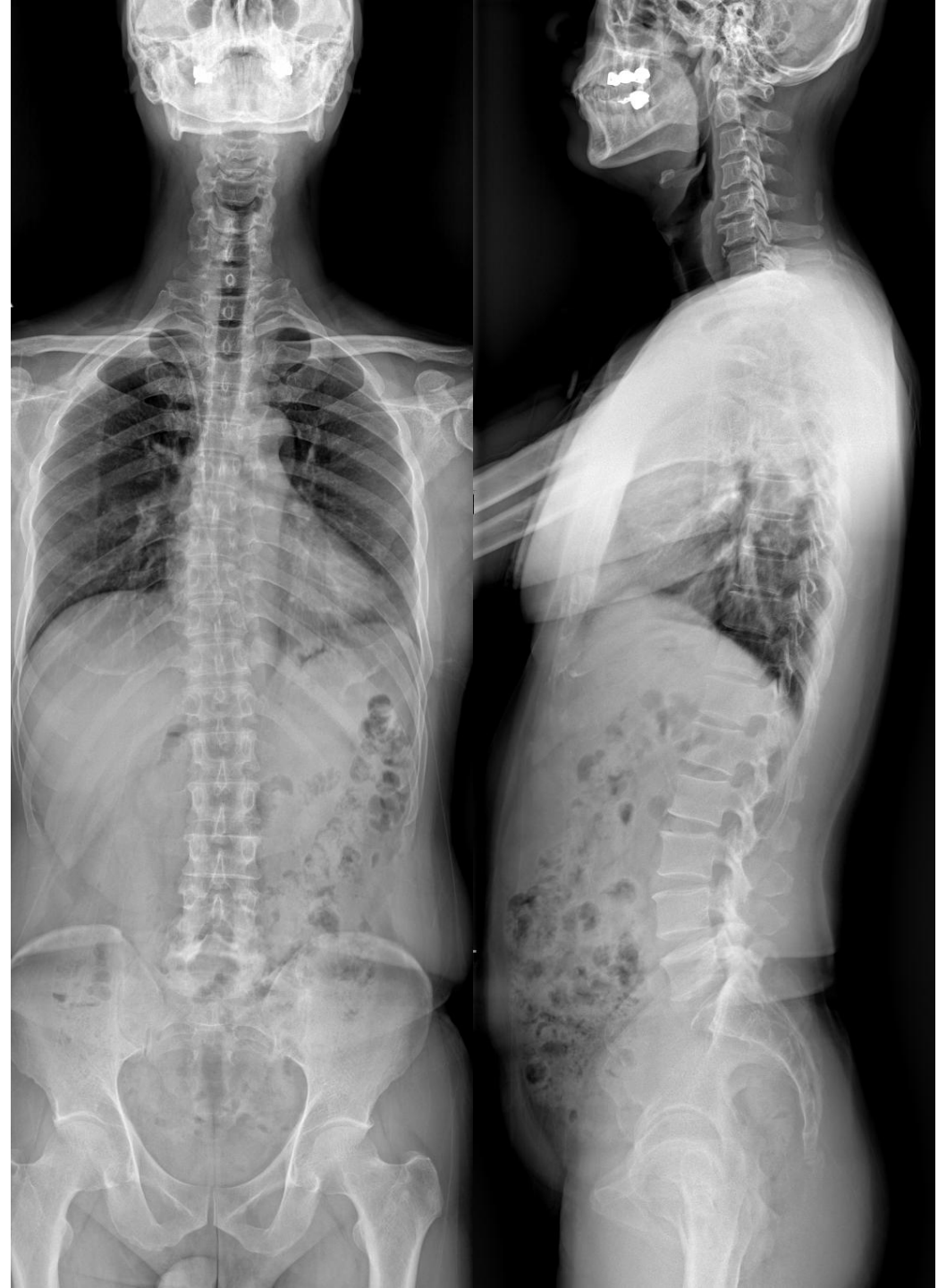Department of Orthopedic Surgery

St. Vincent's Hospital, The Catholic Univ. of Korea

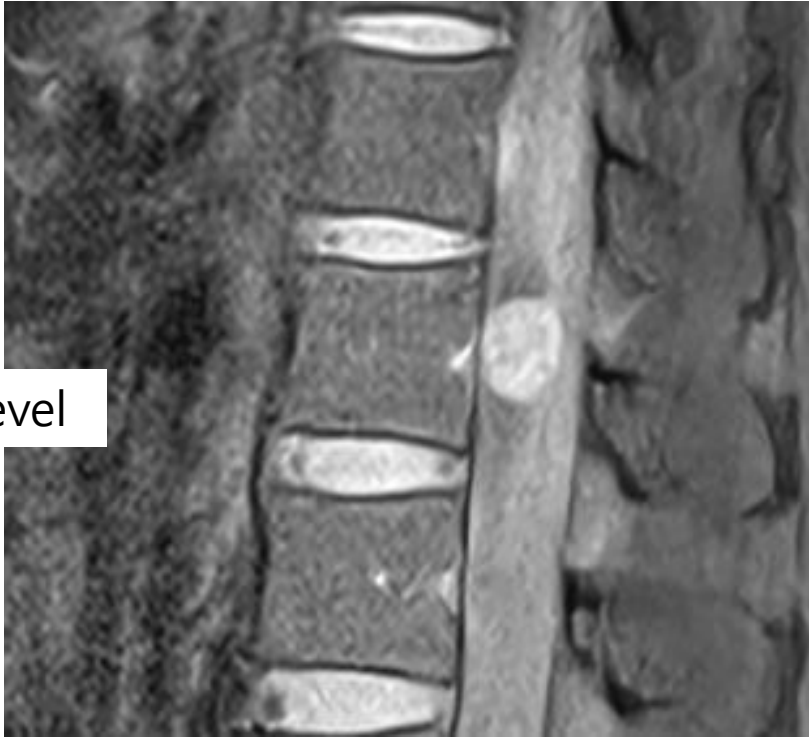
Case

- 51-year-old male
- Low back pain
- Left buttock and whole-leg radiculopathy
- Persistent for 5 months
- Refractory to conservative treatment

- Motor Examination
 - L2 (Hip flexion) : Gr V / **Gr IV**
 - L3 (Knee extension) : Gr V / Gr V
 - L4 (Ankle dorsiflexion) : Gr V / Gr V
 - L5 (Great toe dorsiflexion) : Gr V / Gr V
 - S1 (Ankle plantar flexion) : Gr V / Gr V

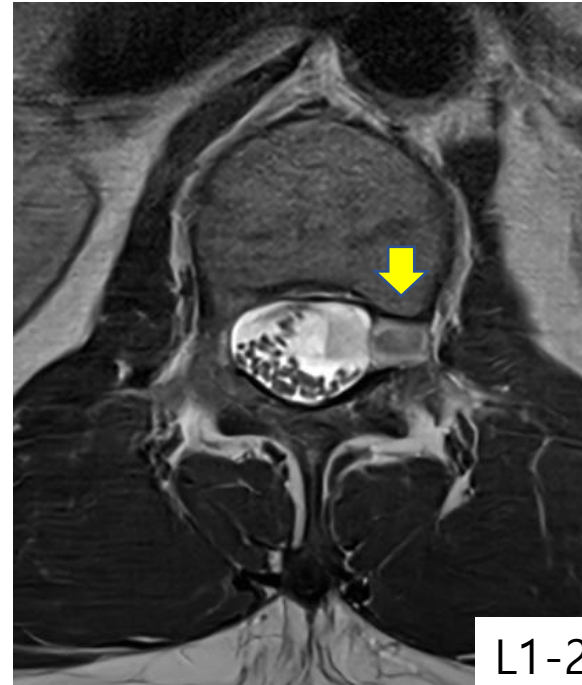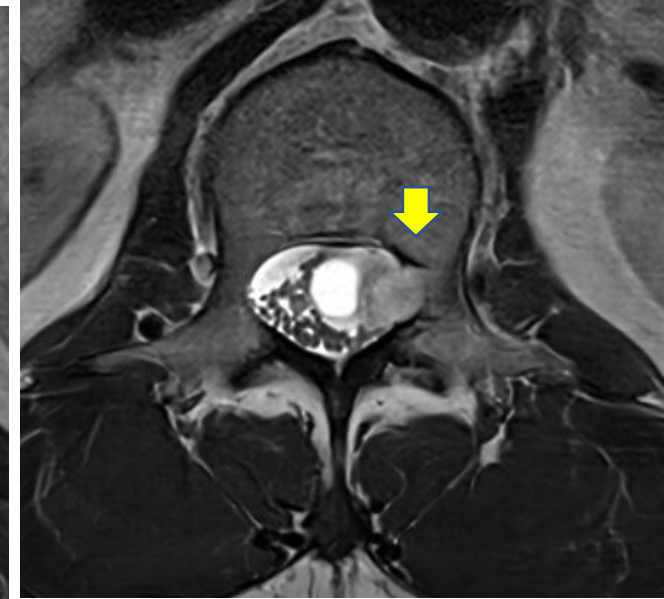
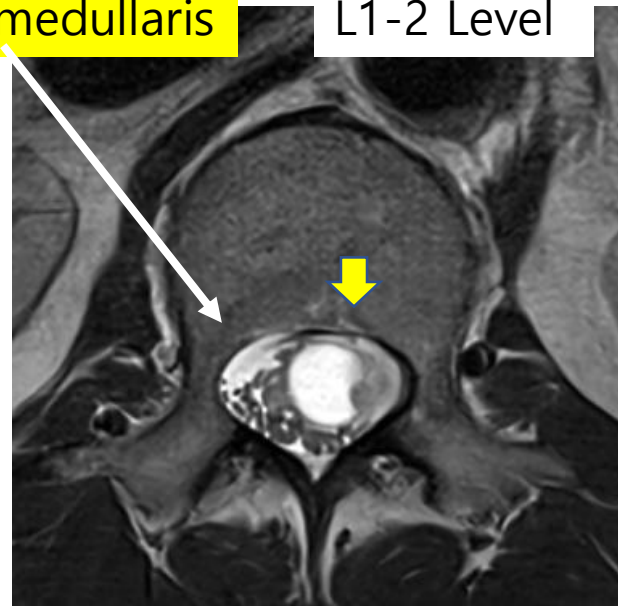


L1-2 Level

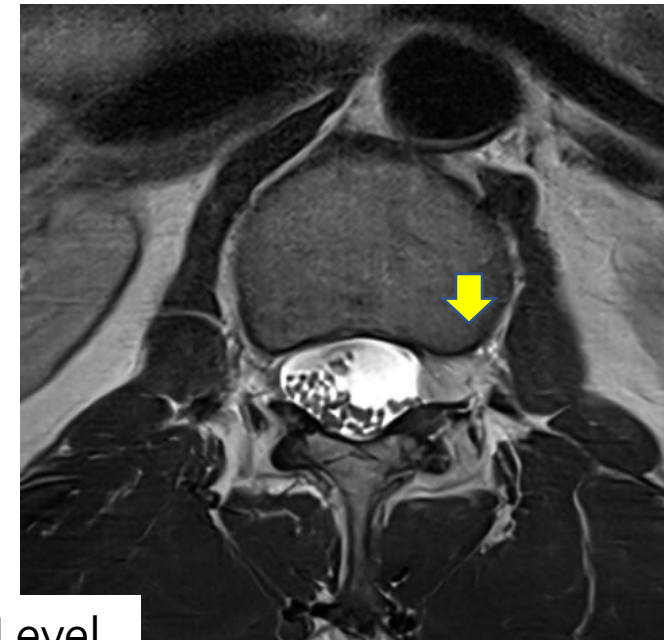


Conus medullaris

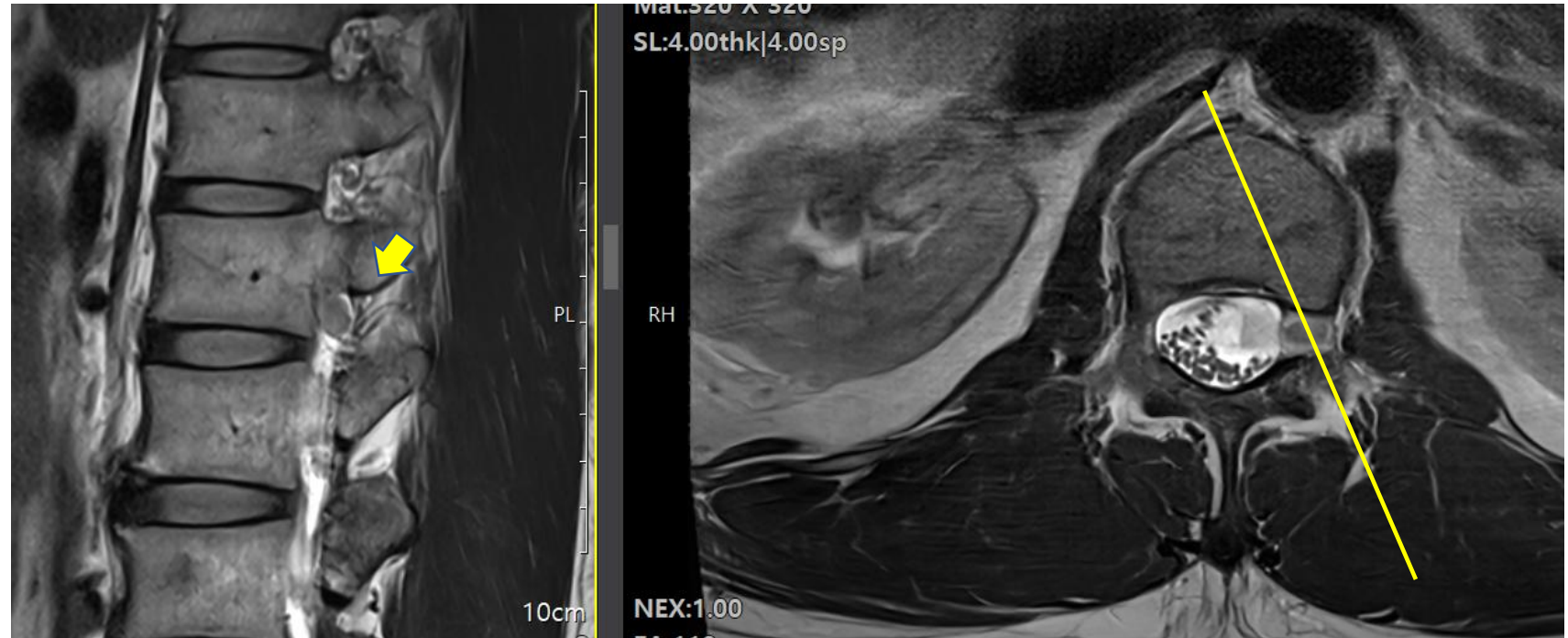
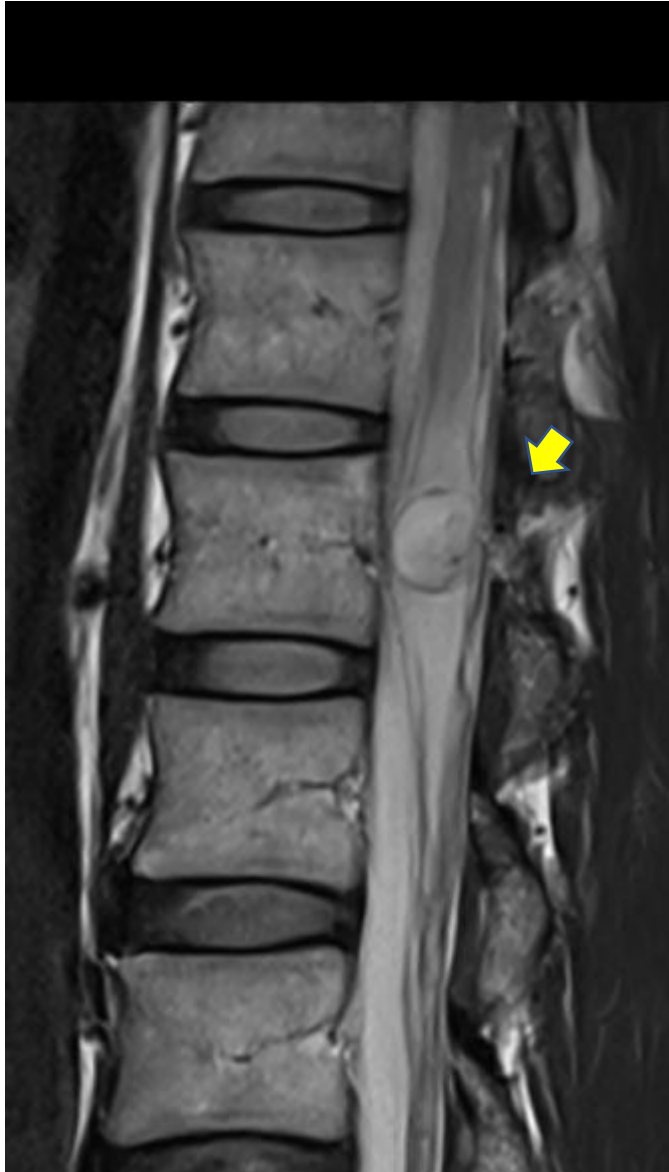L1-2 Level



L1-2 Level

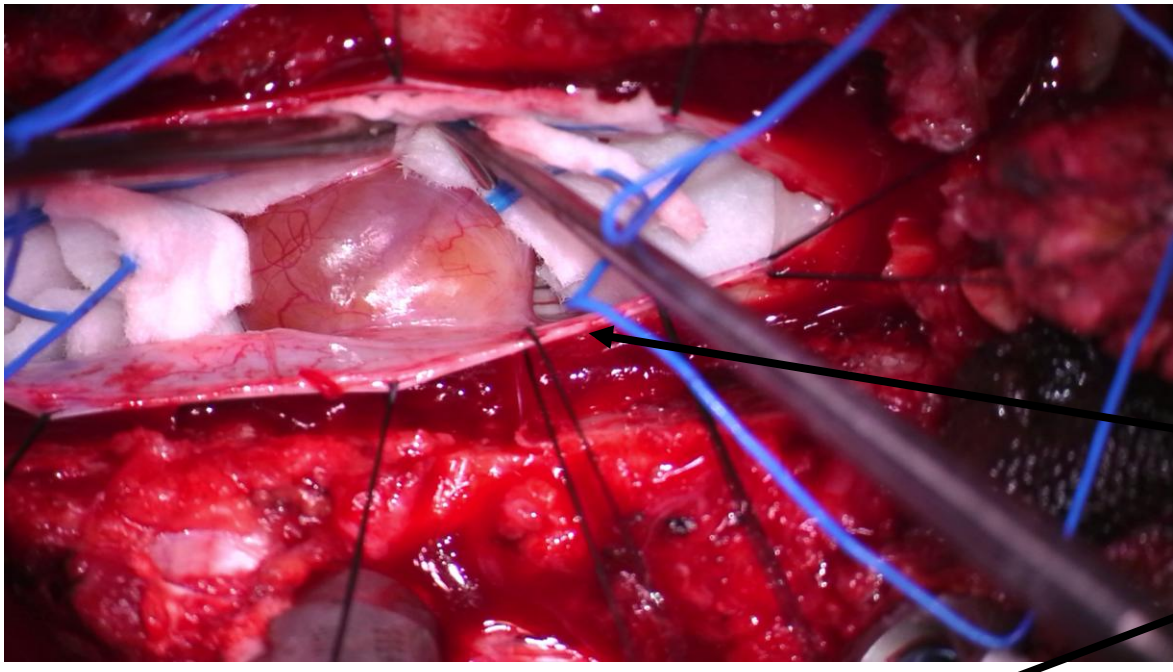


- Fusiform mass
- Intradural extramedullary (IDEM)
- Size: 2.1x1.5 cm
- Differential Diagnosis
 - Neurogenic tumor (e.g. schwannoma)
 - Neurofibroma
 - Malignant peripheral nerve sheath tumor

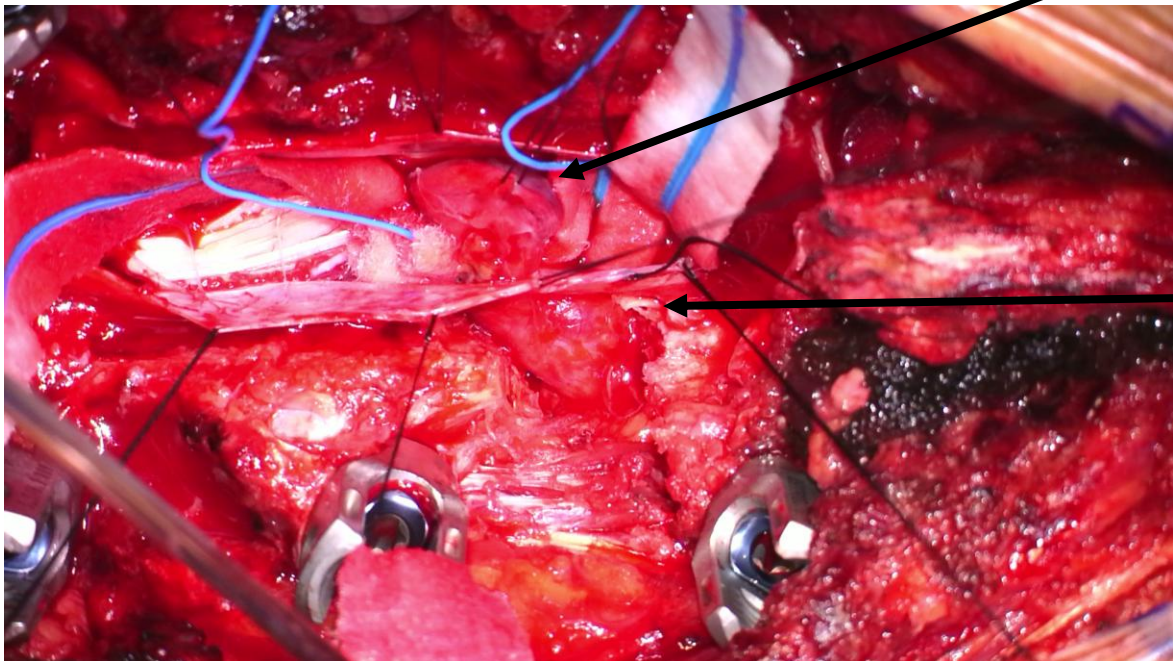


Oblique View

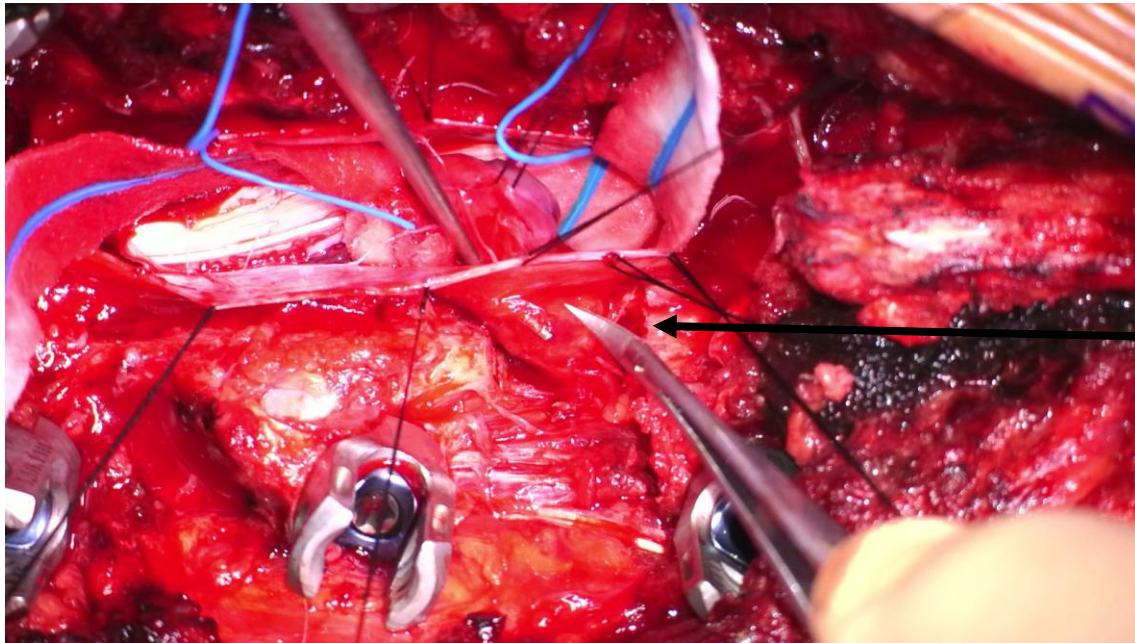
**Lt L1 Nerve Root Origin
Dumbbell shaped Neurogenic Tumor**



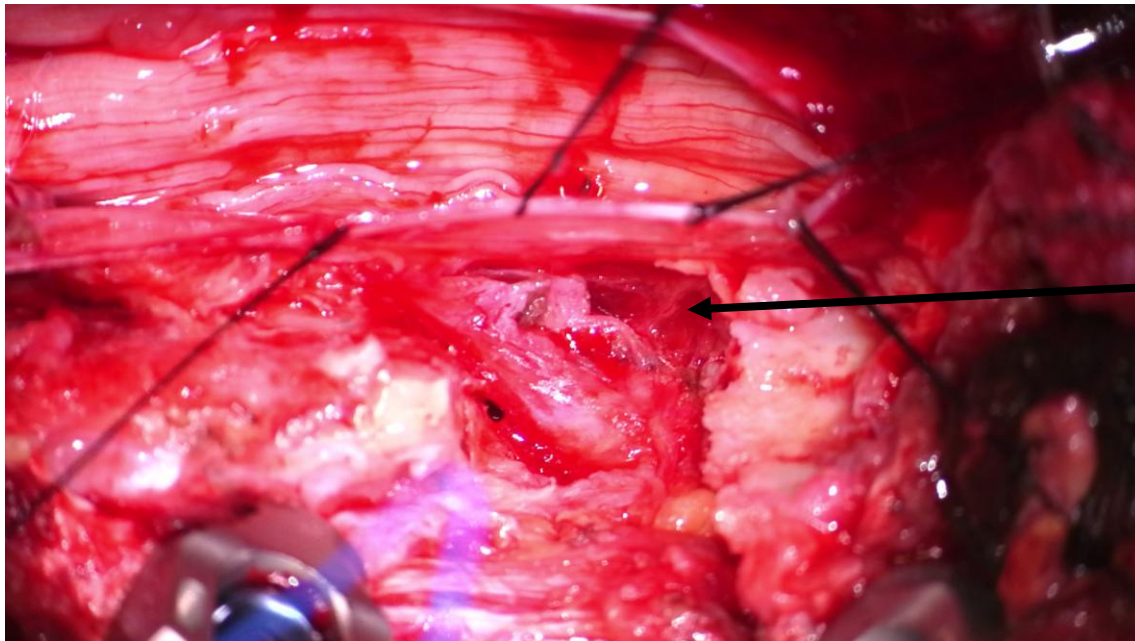
Schwannoma



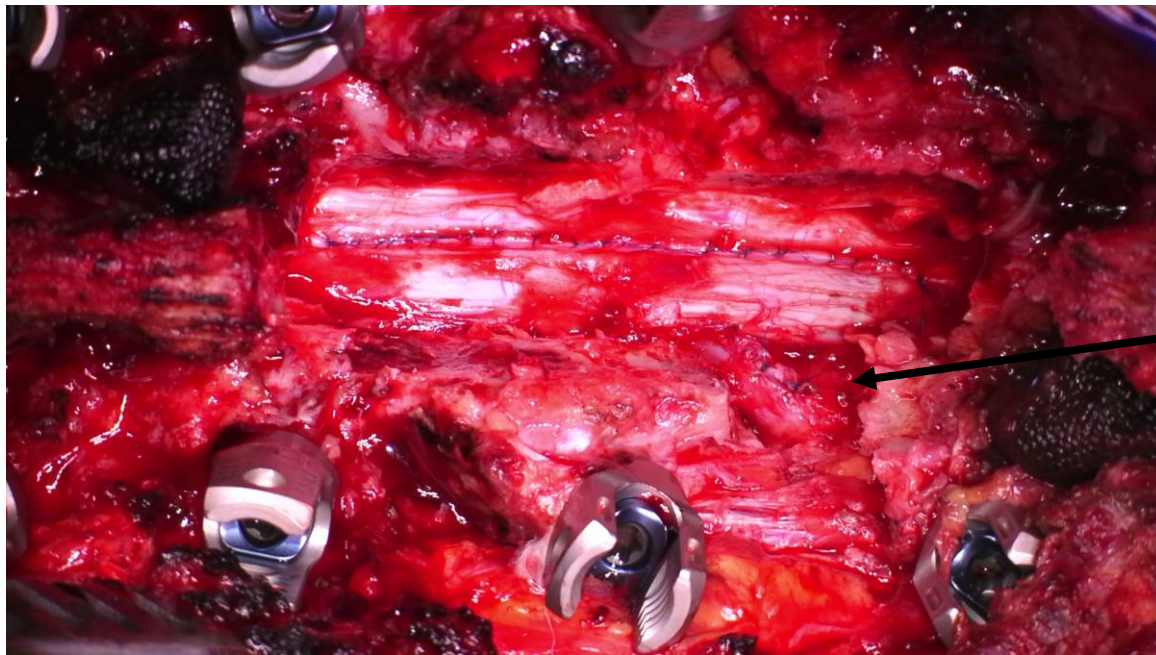
Nerve Root
: Dumbbell shape part
(Total Facetectomy Exposure)



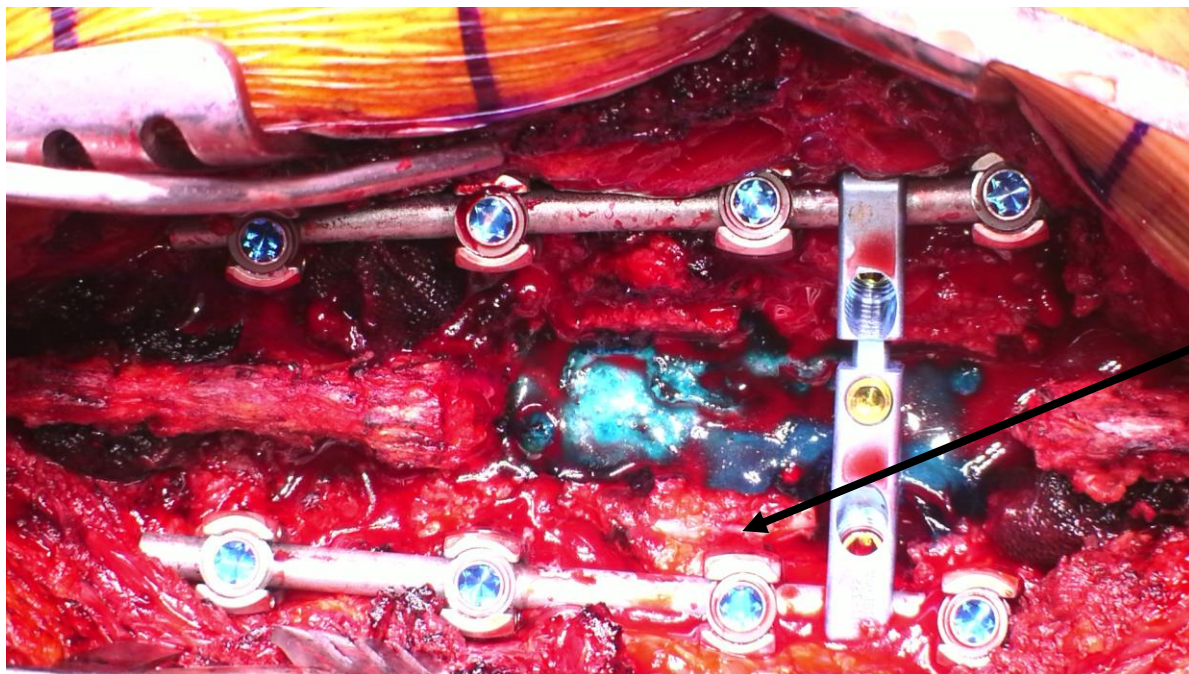
Nerve Root
: Dumbbell shape part
: Dissection



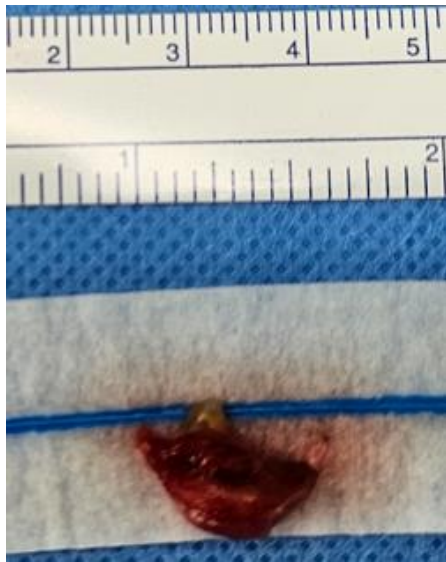
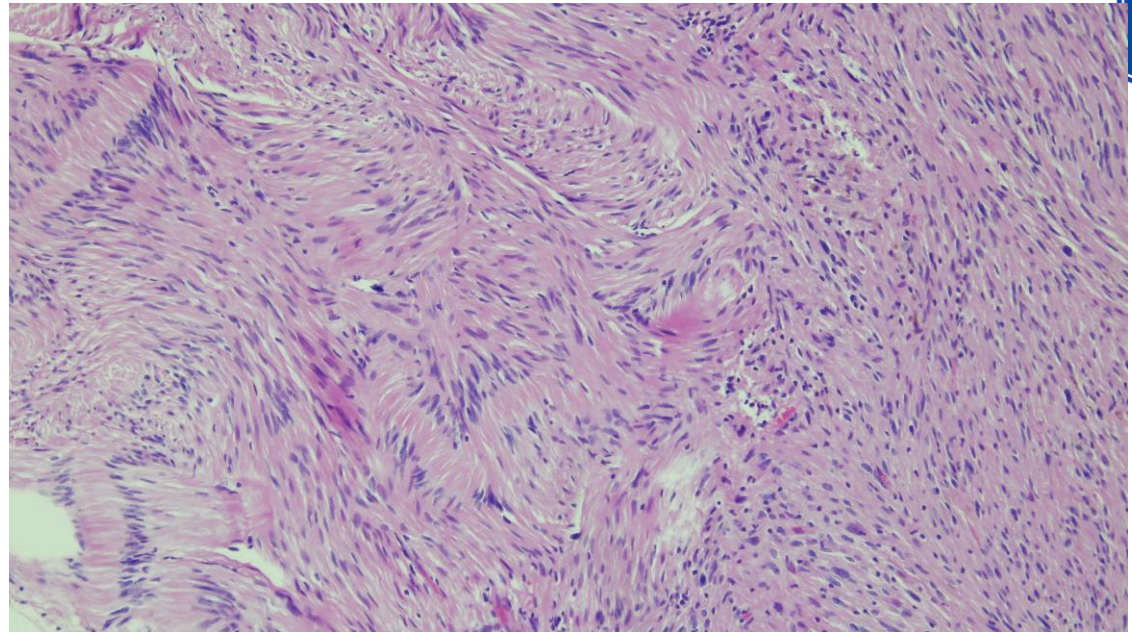
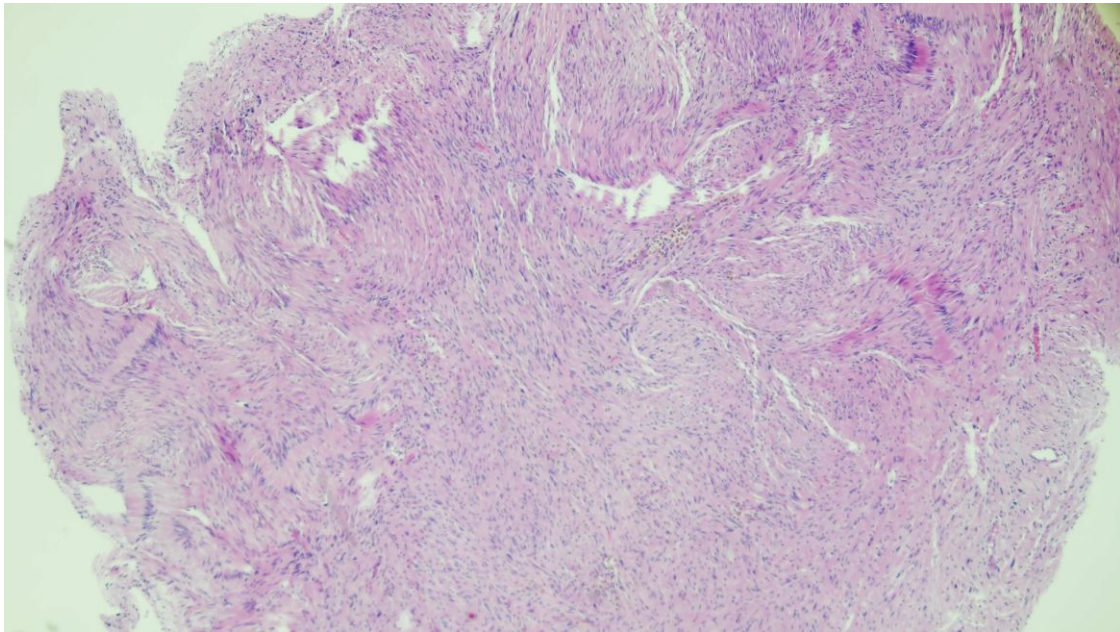
Nerve Root
: Dumbbell shape part
: Debulked



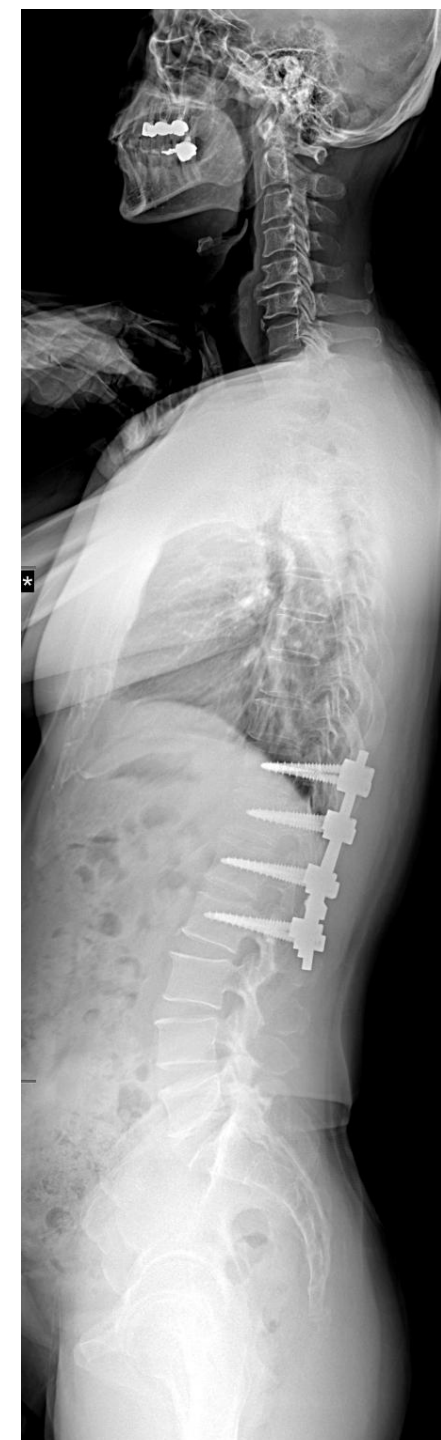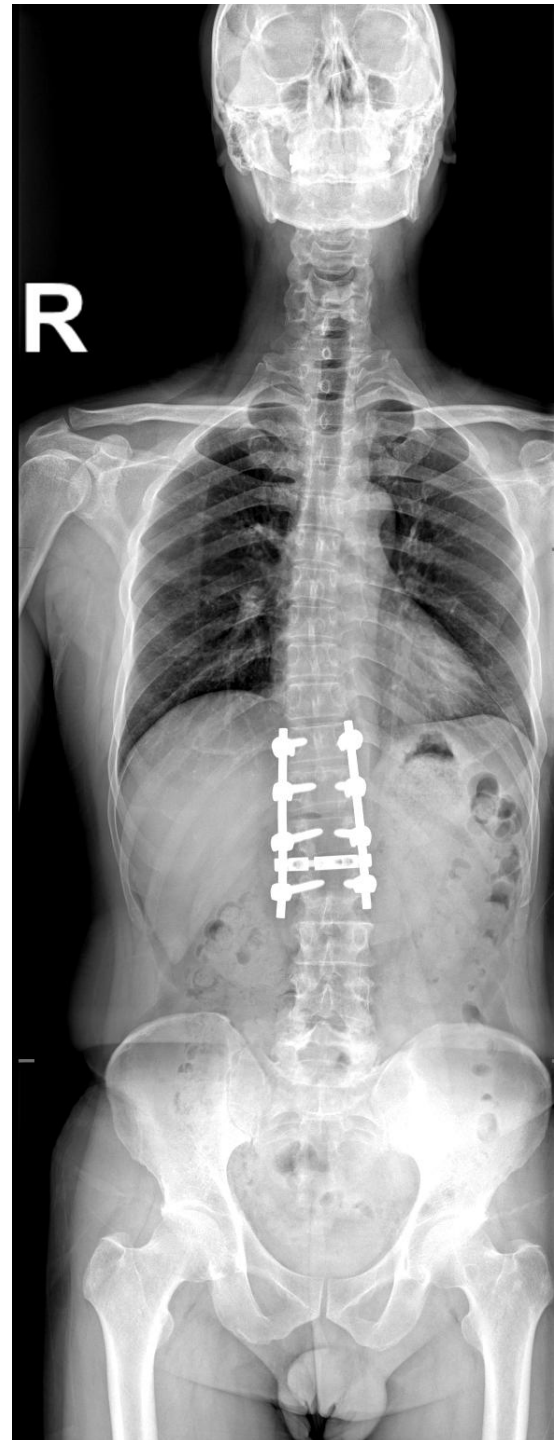
- Nerve Root
- : Dumbbell shape part
 - : Debulked
 - : Sheath Closure – Repaired



- Nerve Root
- : Dumbbell shape part
 - : Total Facetectomy –
 - : Post. Instrumented Fusion



- Schwannoma at L1-2 (left) , dumbbell-shaped
- Laminectomy T12-L1
- **Unilateral facetectomy: L1-2 (left)**
- **PIF T12-L2**
- Pathology: Schwannoma (benign)





Thank you for your
Attention