

INTRODUCTION

The Paradigm Shift: Cervical Disc Arthroplasty (CDA) is a fundamentally different motion-preserving procedure, not merely an alternative implant to ACDF

Clinical Benefit: CDA shows lower Adjacent Segment Degeneration (ASD) rates at 2–7 years compared to the 1958 "gold standard" ACDF (1)

The Caveat: CDA is highly technique-dependent. Improper execution risks heterotopic ossification, suboptimal motion, or implant migration/dislocation (2)

Aim: Understanding the technical nuances and early learning curve is important for surgeons adopting this procedure

METHODS

Study Design: IRB-exempt retrospective cohort study at a single tertiary institution

Scope: Review of the first 100 CDA levels performed by a single fellowship-trained spine surgeon between January 2024 and January 2026

Inclusion Criteria: Single-, double-, or triple-level CDA, and hybrid procedures (CDA-ACDF)

Exclusion Criteria: Active infection, malignancy, or ACDF-only cases

RESULTS

Patient Cohort: 52 patients (100 levels treated); Mean age 54.4 years; Male (61.5%), Female (38.5%)

Indications: Radiculopathy (55.8%); Myelopathy (26.9%); Myeloradiculopathy (15.4%)

Levels Replaced: C3/4 (10%); C4/5 (36%); C5/6 (38%); C6/7 (16%)

The Learning Curve:

- 54% reduction in op time for 2-level CDAs (260 → 120 mins)
- 41.7% reduction in op time for for 3-level CDAs (300 → 175 mins)

Clinical Outcomes:

- Improvement in global cervical lordosis from 9.5° to 15.5° immediately post-op
- Length of Stay (LOS) correlated with myelopathy status
 - Non-myelopathy = 3.9 days
 - Myelopathy = 11.1 days

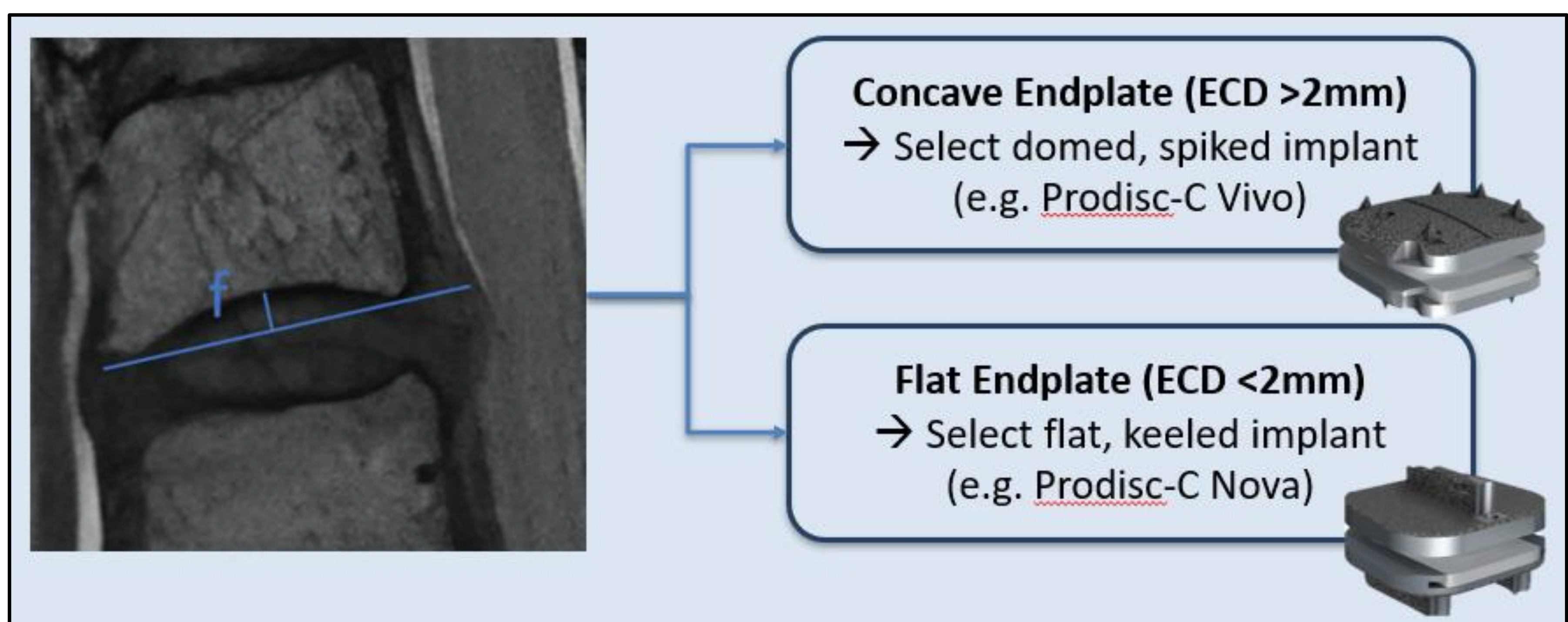
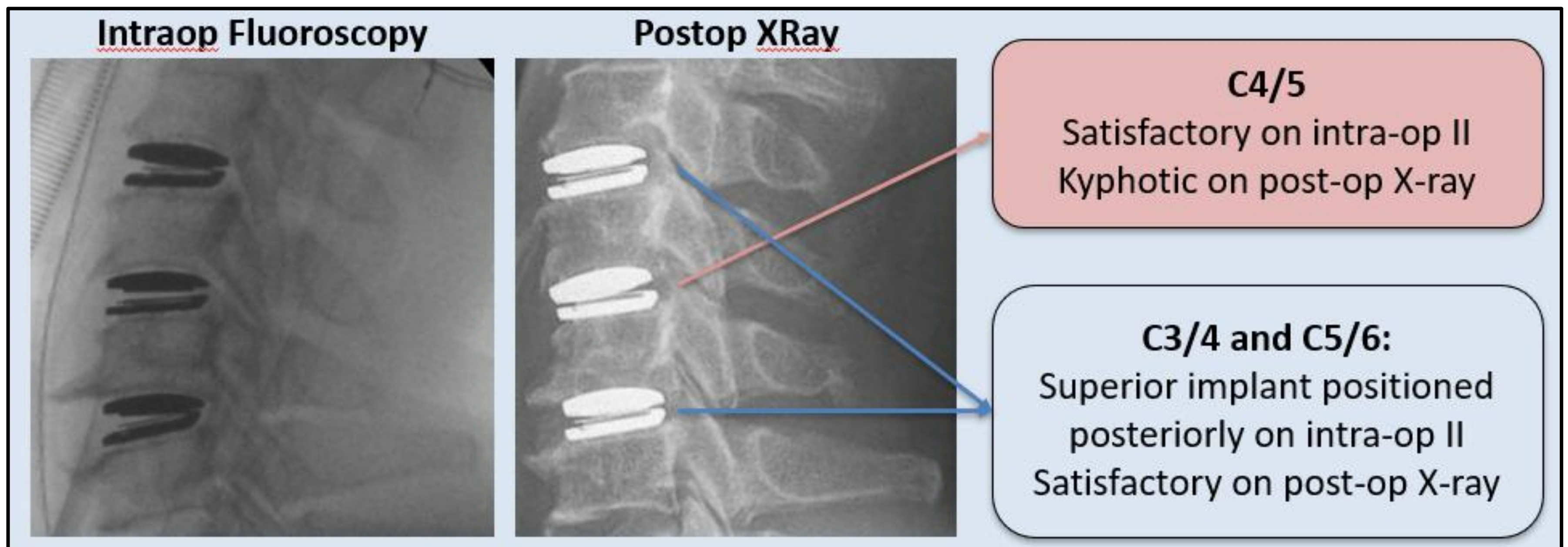
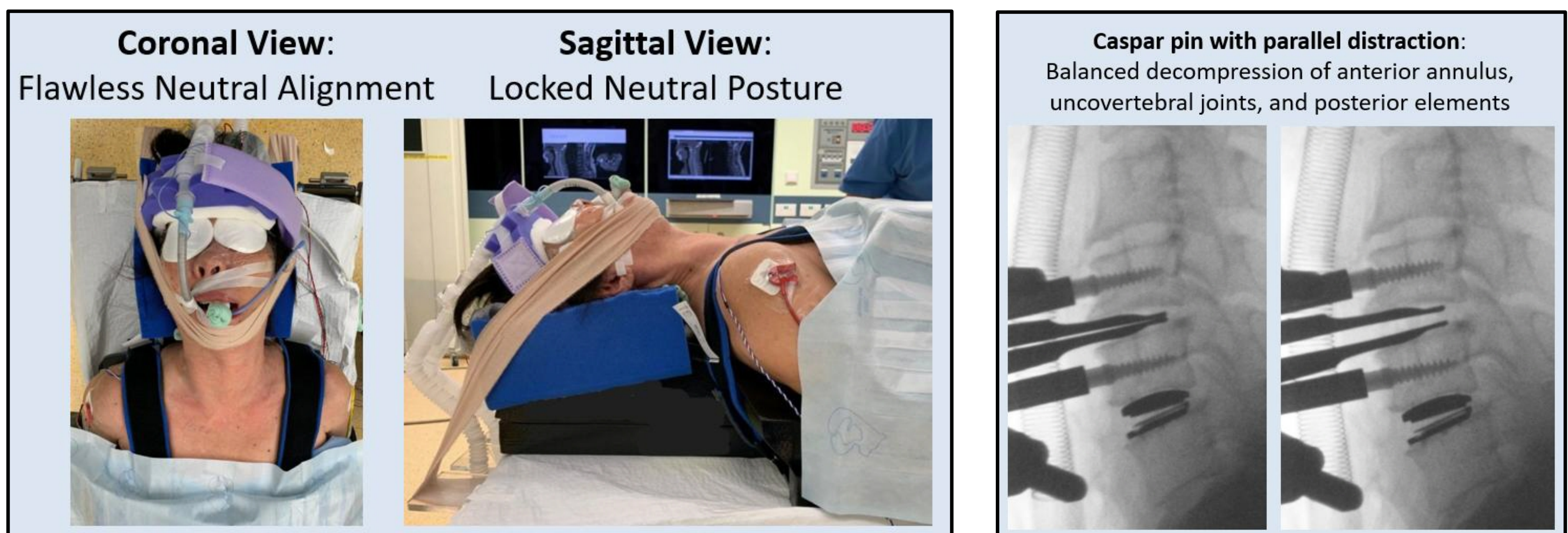
DISCUSSION

The Learning Curve: Experience significantly impacts efficiency. While operative duration and Length of Stay (LOS) increase with procedural complexity (multilevel or hybrid constructs), there is a progressive reduction in operative time as a surgeon gains experience, demonstrating a clear learning curve

Clinical Considerations: The presence of myelopathy significantly prolongs LOS due to higher postoperative recovery demands and the need for closer neurological monitoring compared to non-myelopathy patients.

Technical Mastery: Success is highly technique-dependent. Adherence to the "Surgical Playbook", Pearls I – V, is critical to prevent complications like heterotopic ossification (3) or implant migration

- **Pearl I (Neutral Positioning):** Non-negotiable to avoid postoperative kyphotic or excessive lordotic alignment.
- **Pearl II (Caspar Pin Placement):** Dictates the distraction vector. Parallel distraction is essential to avoid shear or rotational forces.
- **Pearl III (Circumferential Release):** Balanced decompression and judicious endplate preparation (using burs to correct asymmetric unciniate processes) prevent prosthesis tilting.
- **Pearl IV (Midline Placement):** Utilizing interpedicular midpoints ensures correct segment kinematics and avoids abnormal facet forces (4).
- **Pearl V (Tailored Implant Selection):** Use the Endplate Concavity Depth (ECD) concept, a practical refinement that optimizes implant-bone congruency and stability.
 - ECD < 2mm (Flat): Select flat, keeled implants (e.g., Prodisc-C Nova)
 - ECD > 2mm (Concave): Select domed, spiked implants (e.g., Prodisc-C Vivo)



CONCLUSION

Safe & Efficient Adoption: CDA can be performed safely and efficiently during early adoption, provided there is meticulous adherence to fundamental technical principles.

Framework for Success: Achieving optimal prosthesis alignment and preserving physiologic motion relies on neutral patient alignment, parallel distraction, and precise midline implant placement.

Risk Mitigation: Judicious endplate preparation and tailoring implant selection to individual disc morphology (the ECD concept) help minimize risks of malalignment, subsidence, and vertical split fractures (5).

Clinical Implications: These principles provide a reproducible framework for surgeons, facilitating a smoother learning curve and enhancing surgical outcomes during the implementation of CDA.

REFERENCE

1. Findlay C, Ayis S, Demetriades AK. Total disc replacement versus anterior cervical discectomy and fusion: a systematic review with meta-analysis of data from a total of 3160 patients across 14 randomized controlled trials with both short-and medium-to long-term outcomes. The bone & joint journal. 2018;100(8):991-1001.
2. Aurangzeb A, Dinesh SK, Leong D, Teo HLT, Janssen ME, Chew Z. Cervical Disc Arthroplasty Implant Migration and Dislocation: A Systematic Review of Patterns, Risk Factors, and Surgical Outcomes. Global Spine Journal. 2025;21925682251409659.
3. Sheng X-Q, Wu T-K, Liu H, Meng Y. Incidence of heterotopic ossification at 10 years after cervical disk replacement: a systematic review and meta-analysis. Spine. 2023;48(13):E203-E215.
4. Derman PB, Waldorff E, Zhang N, Haddas R. Accuracy of various fluoroscopic landmarks for determination of midline implant placement within the cervical disc space. European Spine Journal. 2021;30(2):554-559.
5. Shim CS, Lee S, Maeng DH, Lee S-H. Vertical split fracture of the vertebral body following total disc replacement using ProDisc: report of two cases. Clinical Spine Surgery. 2005;18(5):465-469.