

**OUTCOMES OF POSTERIOR INDIRECT  
DECOMPRESSION IN  
ACUTE THORACOLUMBAR BURST FRACTURE  
WITH INCOMPLETE NEUROLOGICAL DEFICIT**

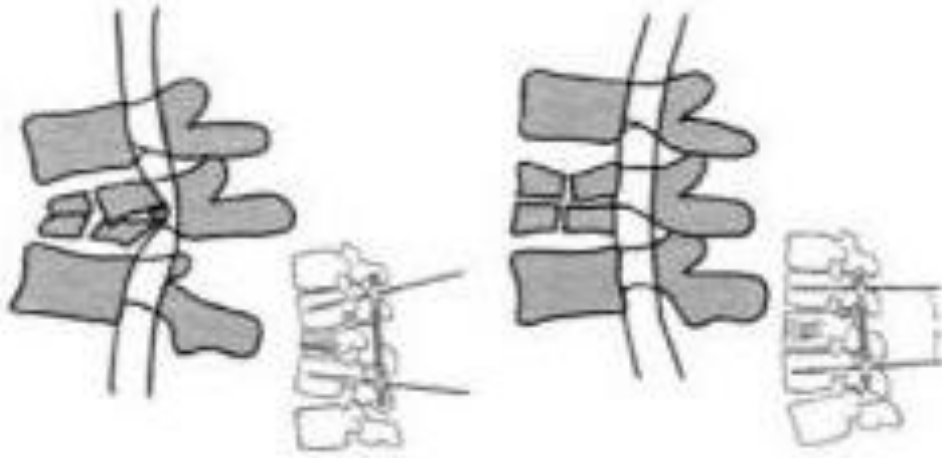
**Dr Maung Maung Lwin**

**M.B.,B.S**

**M.Med.Sc (orthopaedics)**

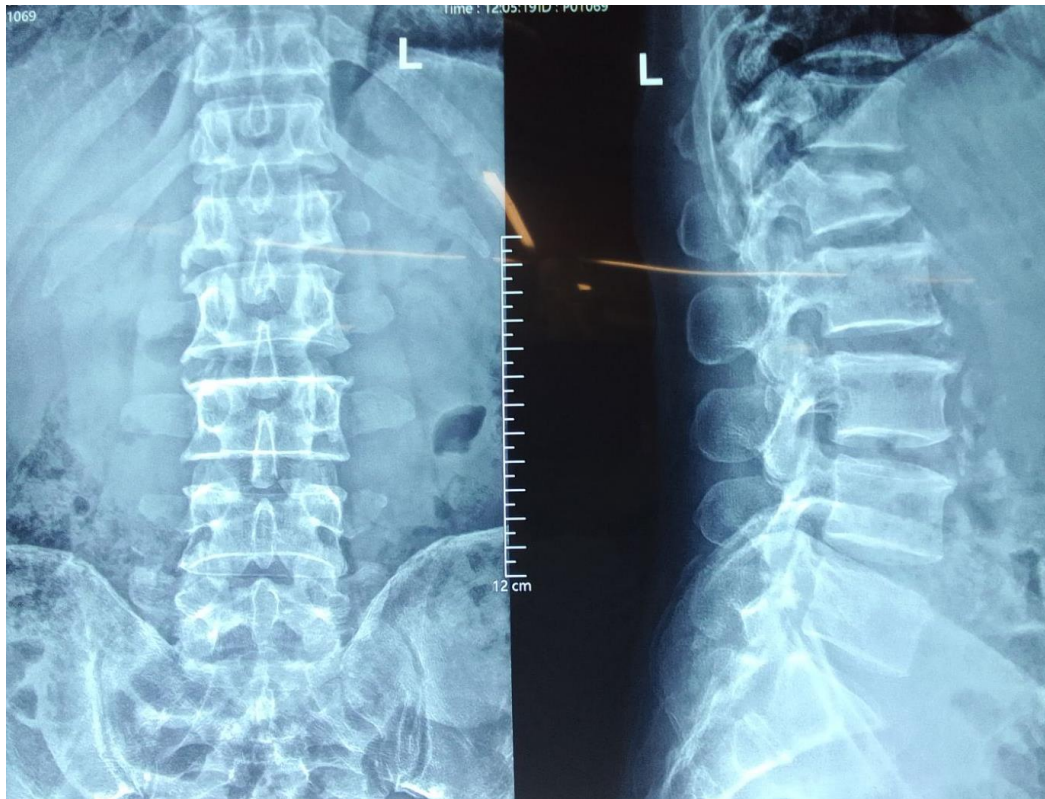
**Candidate of spine surgery**

- Fractures of the spinal column are common musculoskeletal injuries.
- Between 250,000 and 500,000 people get spine injury every year according to the data from WHO (World Health Organization, 11 November 2013).
- Seventy to 80% of spinal fractures occur at thoracolumbar and lumbar region, with 17% being burst fractures.
- Neurological injury complicates 19% to 50% of spine fractures (Patil et al., 2016).
  
- Instead of a constant pressure of the bone fragments directly on the spinal cord, the incomplete neurological deficit occurred due to the dynamic instability of the vertebra itself.
- Posterior indirect decompression is a posterior approach which utilizes the posterior longitudinal ligament (PLL) by which a longitudinal distraction force is placed on the band, realigning the fracture fragments of the vertebral body and reducing any pressure on the cord itself. (Ligamentotaxis).

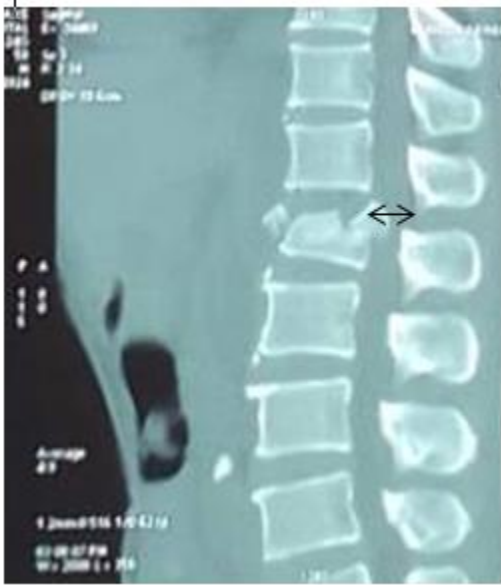

Procedure of ligamentotaxis

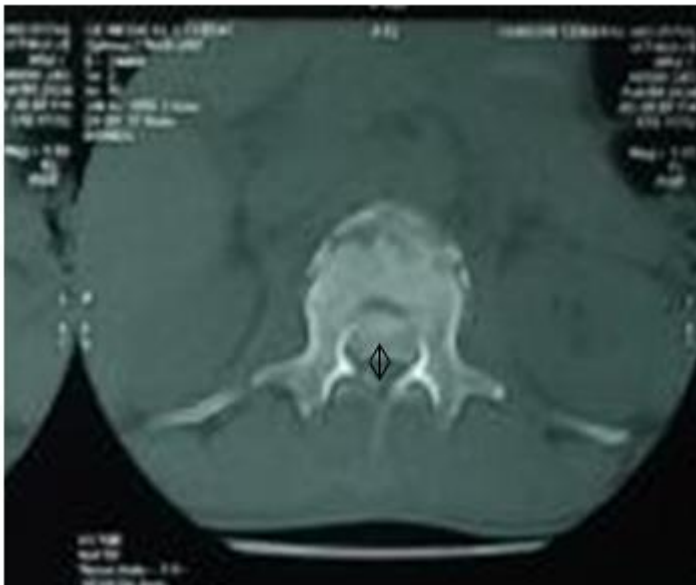## Case sample



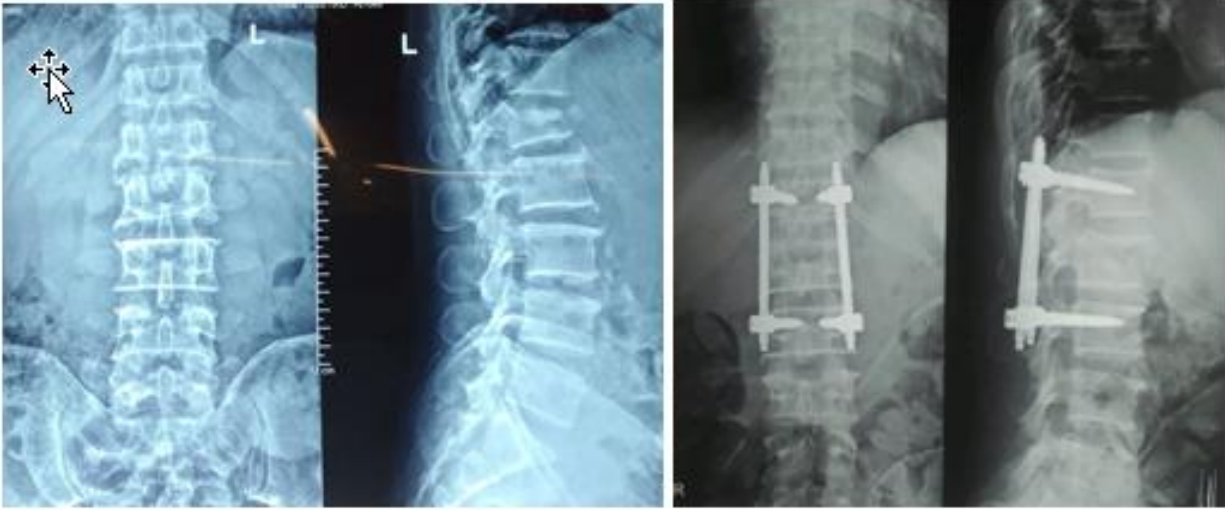- 58 year old gentleman, manual worker, fall from height about 15 ft



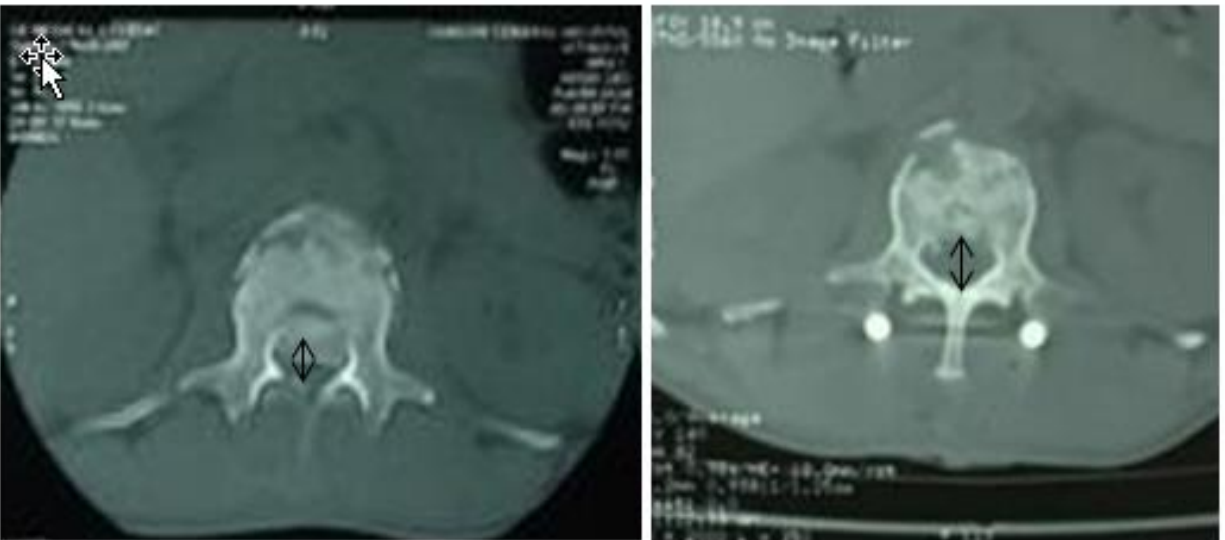
**Pre-operative sagittal view CT scan**  
**AO A3**



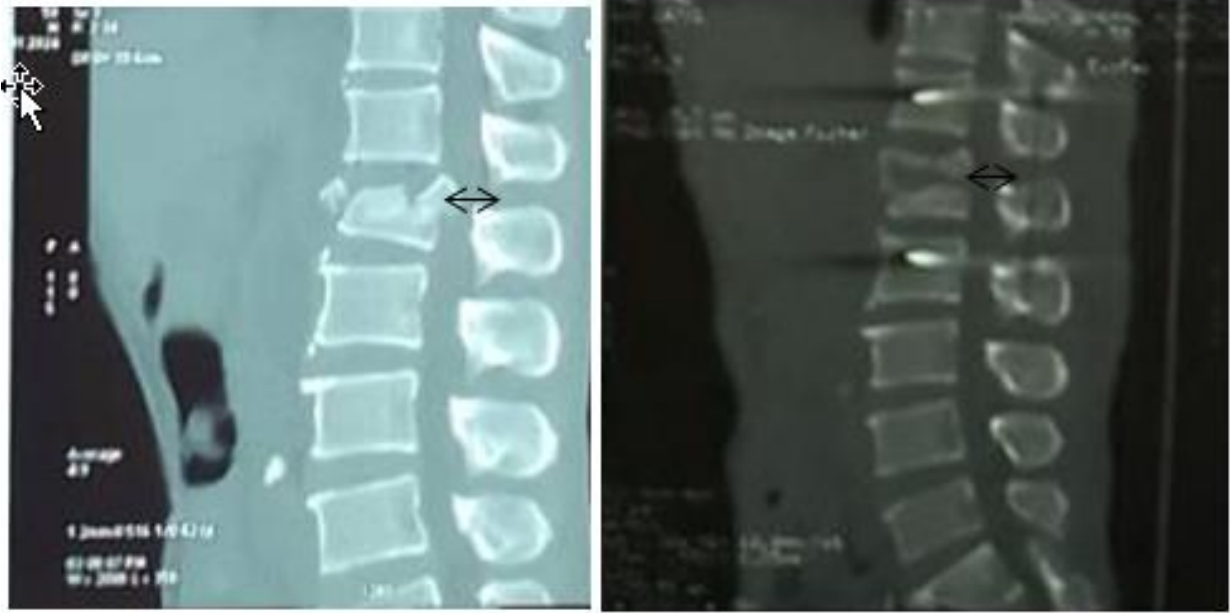**Pre-operative axial view CT scan**



**Pre-operative and post-operative x-rays**



**Pre-operative and post-operative axial views CT scan**



**Pre-operative and post-operative sagittal CT scan**